

EXTENSIVE COMPLEX ODONTOMA CAUSING CHRONIC MAXILLARY SINUSITIS : AN UNCOMMON PRESENTATION

Akhilesh Kumar Singh* , Naresh Kumar Sharma, Ajit Vishwakarma***,
Shankar Singh*** and Adit Srivastava******

* Main author ,Assistant Professor, Department of Oral & Maxillofacial Surgery,
Faculty of Dental Sciences, IMS, Banaras Hindu University, Varanasi (U.P), India

**Professor & Head, Department of Oral & Maxillofacial Surgery, Faculty of Dental Sciences,
IMS, Banaras Hindu University, Varanasi (U.P), India

*** Junior Resident, Department of Oral & Maxillofacial Surgery, Faculty of Dental Sciences, IMS
Banaras Hindu University, Varanasi (U.P), India

**** Corresponding author: Associate Professor, Department of Oral Medicine & Radiology,
Faculty of Dental Sciences, IMS, Banaras Hindu University, Varanasi (U.P), India

Abstract

The pathological conditions of the jaw which are group of most common odontogenic neoplasm and fully expressing odontogenic differentiation are odontomas. They are considered as hamartomatous or developmental odontogenic anomaly rather than a true neoplasm, characterized by slow growth and non aggressive behavior. The structural composition of odontomas are enamel, dentin, cementum along with both epithelial and mesenchymal tissues and they are classified by world health organization (WHO) in to two types based on their gross anatomical and radiological features: the complex and the compound odontoma. We report a case of 20 years old female with a large complex odontoma involving right posterior maxilla and maxillary sinus with clinical features suggestive of maxillary sinusitis. The tumor was excised en bloc along with impacted molar through intraoral approach.

Keywords: complex odontoma, maxillary sinus, odontogenic tumour, sinusitis

Introduction

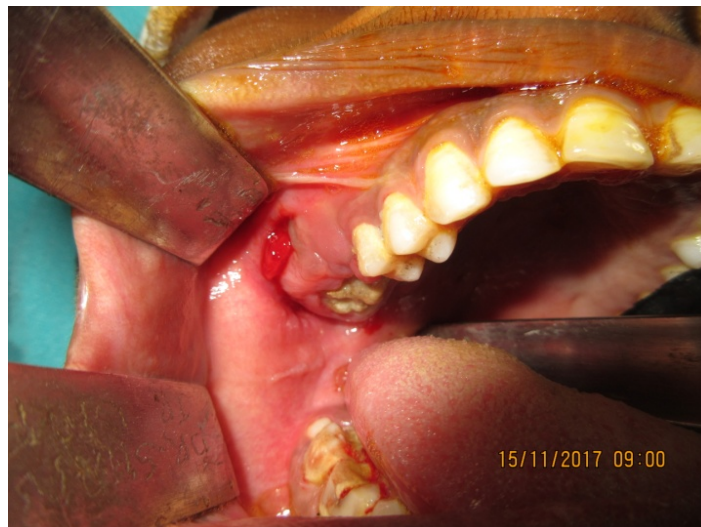Broca in 1863 introduced the term “odontoma”. Odontomas are most common odontogenic tumours resulting from growth of mesenchymal and epithelial cells which are completely differentiated. They are described as mixed tumours consisting of both mesenchymal and epithelial cells and exhibiting different structures of dental tissue i.e. enamel, dentin, cementum and pulp.¹ Another odontogenic tumours mixed tissues are ameloblastic fibroma and ameloblastic fibro-odontoma.²

WHO classified (1992) odontomas in to two categories based on their gross anatomical and radiological features (complex and compound odontoma). Complex odontomas are characterized by no discernable structure and amorphous mass of mineralized dental tissue are arranged in less orderly fashion, whereas in compound odontoma structures are more orderly arranged and can be identifiable as numerous miniature or tooth like structures which are known as denticles.³ The reported etiology

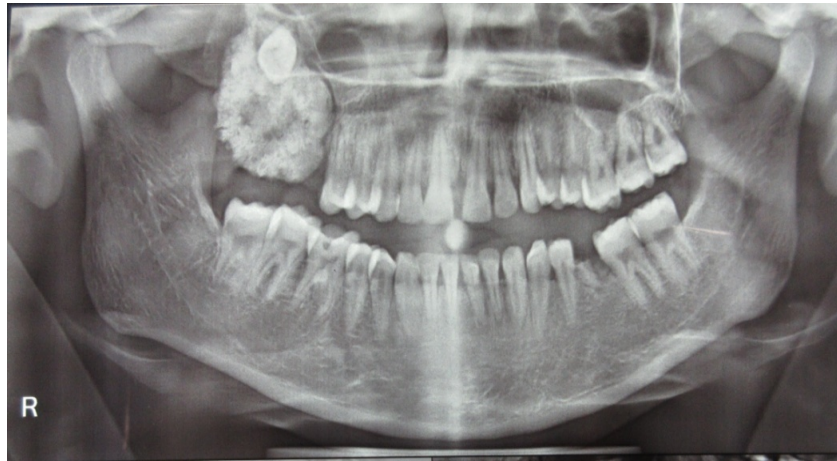of odontomas are local infection and trauma, growth pressure, hereditary, genetic mutations (Gardner's syndrome & Hermann's syndrome) & developmental influences but the exact etiology is unknown. These tumours are formed during tooth development and detected most commonly in 2nd and 3rd decade of life on routine dental radiographic examination, but may be found at any age with no gender prediction.^{4,5} Maxilla is most commonly involved in maxillofacial region with incidence of 22% to 67% and occurrence ratio of compound to complex odontoma is 2:1.^{6,7} Chronic maxillary sinusitis due to infected oro-antral fistulae and periapical abscess extending to regional sinus is relatively frequent clinical finding but due to odontoma is a rare entity.⁸ Surgical management of these lesions are en bloc excision and curettage as recurrence is extremely rare.

Case report

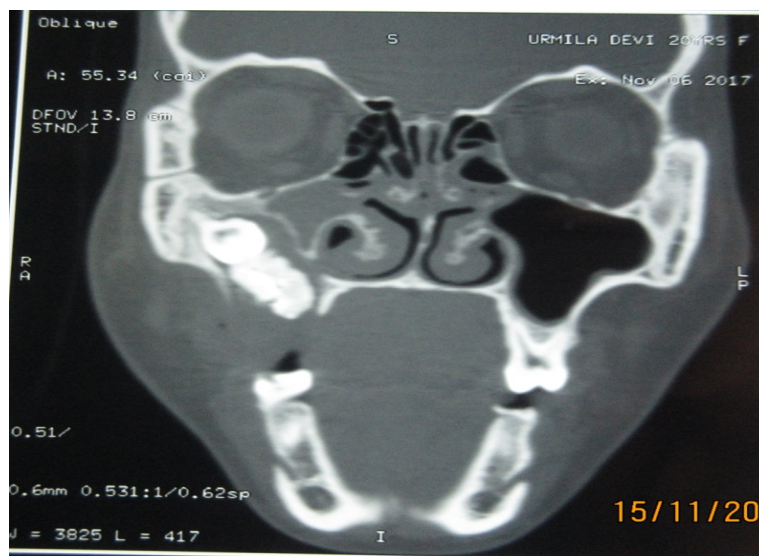
A 20 years old female was referred to us with the chief complaint of heaviness and pain on right side of face for last two years. Earlier she underwent treatment by the physician which did not relieve the symptoms. Unilateral nasal obstruction with change in voice and fetid breath was observed. Intraoral examination showed the rough yellowish mass with hard consistency associated with inflamed regional soft tissue in right maxillary posterior molar region (fig.1).



The orthopantomogram revealed the presence of well defined radio-opaque mass in right maxilla extending from alveolus to maxillary sinus and pushing molar teeth superio-laterally (fig.2).



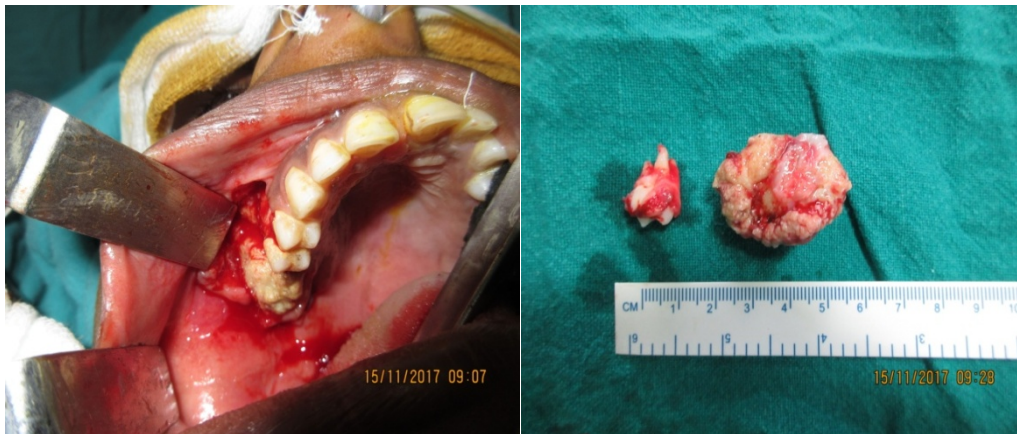Computed tomography revealed a well defined irregular calcified mass lesion measuring 3x2.4x3cm is noted in posterior aspect of the right side of maxilla. The lesion is causing the mass effect in the form of indentation and cortical erosion of floor of ipsilateral maxillary sinus. A tooth is seen impacted near the apex of the pathology (fig.3).



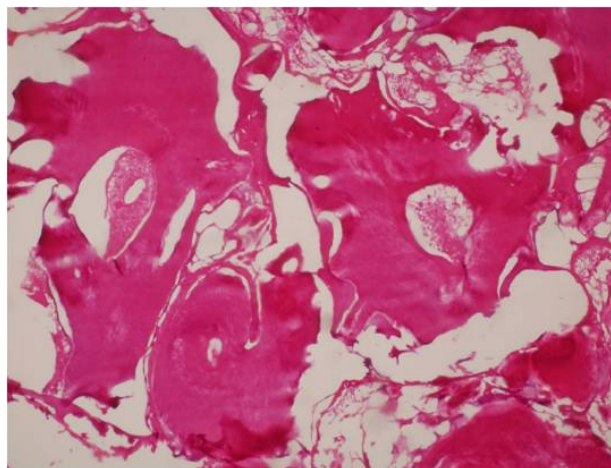
The clinical and radiographic features are consistent with odontoma and communication of the lesion with oral cavity favours the occurrence of the symptoms of maxillary sinusitis. Once the clinical symptom of patient was relieved after antibiotic

therapy with nasal decongestant, the excision was planned through intraoral approach under general anaesthesia.

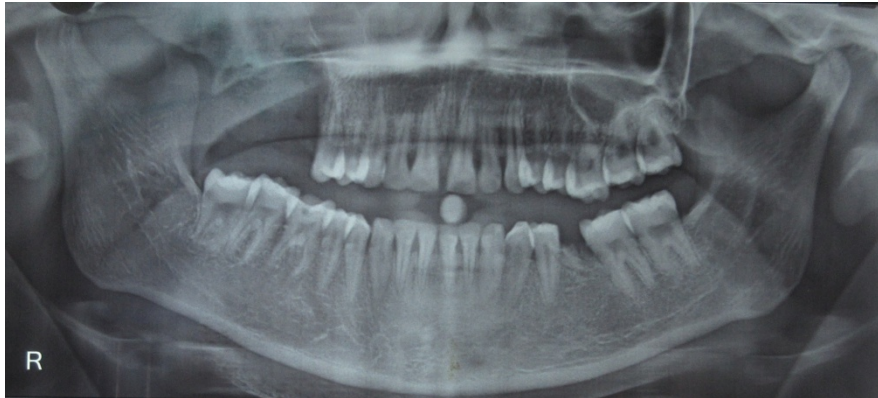
After elevation of muco-periosteal flap, an osteotomy was made around the lesion through sharp osteotome to facilitate detachment and removal of the lesion, followed by copious irrigation of maxillary sinus (fig-4,5).



Postoperative healing was uneventful. Histopathological examination showed an irregular arrangement of dental tissues such as enamel, dentin and cementum, together with odontoblastic cells in pulp tissue, findings that confirmed the diagnosis of complex odontoma(fig.6).



The Panoramic radiograph reveals complete excision of the lesion with impacted tooth (Fig-7).



Discussion

Gebell, James & Pyne classified the odontoma on the basis of their developmental origin as composite (epithelial & mesenchymal), epithelial and connective tissue. Thoma and Goldman (1946) divided the odontomas as compound composite, complex composite, germinated composite, dilated and cystic odontomas.⁹ When the classification system was restricted as in WHO, to those proliferations of odontogenic cells that are enough matured to the stage of differentiation in enamel and dentin, two types were recognized as compound and complex odontomas and this differentiation usually made through comparison of degree of morphodifferentiation.

Odontomas are unnoticed unless and until symptomatic or accidentally diagnosed on routine dental radiological studies. Series of sequelae may be associated with these lesions are ectopic tooth eruption, displacement and malformation of adjacent tooth. Growth pressure exerted by odontomas may cause regional tooth germ loss, diastema, pain, devitalization of tooth and bone resorption.¹⁰

Cabocet *al* reported cases of maxillary odontomas associated with chronic congestion of the maxillary sinus, which was consistent with the present case in which odontoma extending to the maxillary sinus leads to communication between maxillary sinus and oral cavity which causes marked discomfort the patient.¹¹ The mechanism of eruption in oral cavity is different from normal tooth because the odontomas lack root formation and associated periodontal ligament, the gradual increasing in size leads to resorption of alveolar process and exposure in to the oral cavity.¹²

Generally complex odontomas are 3-4cm in size to be evident as clinically symptomatic. Radiographically they are present as a well defined radio-opacity, and foci of variable density with irregular margins. The density of odontomas are greater than bone and greater than or equals to tooth structures and the lesions are surrounded by

radiolucent halo with thick sclerotic bone. Singh *et al* described ameloblastic fibroodontoma and complex odontoma as similar entity the basis of clinical and radiological presentation. Histopathological examination is mandatory to differentiate them. The relative arrangement of the soft tissues and the stage of development of the involved tooth are useful criteria for diagnosis.¹³ The radio-opaque findings of complex odontomas in maxillary sinus can be characteristic of some another maxillofacial lesions such as cementoblastomas, ossifying fibromas, osteoblastomas, calcifying odontogenic tumours & ameloblastic fibro-odontomas.¹⁴ Treatment of choice is conservative surgical excision through transoral approach, and a transcutaneous approach may be required in case of more extensive maxillary odontoma.

Conclusion

Odontomas are common odontogenic tumours that can be easily diagnosed as incidental finding and surgically managed. However if no sign and symptoms appears, the lesion may not be detected for many years without any clinical manifestation, but these tumours should not be underestimated since large odontomas may be associated with rare and aggressive clinical features that can leads to serious disorders like chronic maxillary sinusitis as seen in our case.

References:

1. Bordini J Jr, Contar CM, Sarot JR, Fernandes A and Machado MA(2008). Multiple compound odontomas in the jaw: case report and analysis of the literature. *J Oral Maxillofac Surg*;66 (12): 2617-2620.
2. Kramer IRH, Pindborg JJ and Shear M (1992) The WHO histological typing of odontogenic tumors. *Cancer* 70: 2988–2994.
3. Shafer WG, Hine MK, Levy BM(1993) Text book of Oral Pathology, 4th ed. Philadelphia: WB Saunders Company;308-312.
4. Gorlin RJ (1970) Odontogenic tumors. In: Thoma's oral pathology. Mosby, St. Louis, pp 497–501.
5. Barnes L (2001) Surgical pathology of the head and neck. Marcel Dekker, New York Basel, pp 1595–1597.
6. Owens BM, Schuman NJ, Mincer HH, Turner JE and Oliver FM(1997) dental odontomas: a retrospective study of 104 cases. *J Clin Pediatr dent*;21(3):261-264.
7. Miki Y, Oda Y, and Iwaya N, et al (1999) Clinicopathological studies of odontoma in 47 patients. *J Oral Sci*;41(4):173-176.
8. López M, Monserrat JR, Kolanczak K, Piñeiro Z, Gañan L, and Costey M(2005). Sinusitis odontógenay fístula orosinusal. Rinitis, rinosinusitis, poliposis nasal. Ponencia Oficial de la SEORL y PCF,. Badalona. EUROMEDICE Ediciones Médicas: 7721-330.

9. Singh G, Singh RK and Das S(2015). Large Complex Odontome of Maxilla: Report of a Case and Literature Review. *Oral Maxillofac Pathol J*;6(1):572-574.
10. Sales MA, and Cavalcanti MG(2009). Complex odontoma associated with dentigerous cyst in maxillary sinus: case report and computed tomography features. *DentomaxillofacRadiol*;38:448-552.
11. Cabov T, Krmptotic M, Grgurevic J, Peric B, Jokic D, and Spomenka Manojlovic S(2005). Large complex odontoma of the left maxillary sinus. *Wien Klin Wochenschr*;117/21-22,780-3.
12. M. SolukTekkesin, S. Pehlivan, V. Olgac, N. Aksakall, and C. Alatl, (2012)., "Clinical and histopathological investigation of odontomas: review of the literature and presentation of 160 cases," *Journal of Oral and Maxillofacial Surgery*, vol. 70, no. 6, pp. 1358–1361
13. Singh AK, Kar IB, Mishra N, Sharma P(2016). Ameloblasticfibroodontoma or complex odontoma: Two faces of the same coin. *Natl J Maxillofac Surg*;7:92-5.
14. Lee CH, Park GJ. Complex and compound odontomas are clinico-pathological entities(2008). *Basic Appl Pathol*; 1:330-33.

Figure Legends:

- Fig.1- Intraoral view showing a hard yellowish mass exposed in oral cavity.
- Fig.2- Pre-operative panoramic radiograph showing radio-opaque mass in right maxilla.
- Fig.3- Coronal CT demonstrating a calcified mass in relation to right maxillary sinus.
- Fig.4- Exposure of the lesion.
- Fig.5- Excised specimen.
- Fig.6- Histopathological examination showed an irregular arrangement of dental tissues with odontoblastic cells in pulp tissue.
- Fig.7- Post-operative panoramic radiograph showing complete excision of the lesion with impacted tooth.

